oral surgery
oral medicine
oral pathology

With sections on endodontics *and* dental radiology

Volume 38, Number 5, November, 1974

oral surgery

Anatomic variations in the stylohyoid chain and their possible clinical significance

Jack Frommer, Ph.D., Boston, Mass.*

SCHOOLS OF MEDICINE AND DENTAL MEDICINE, TUFTS UNIVERSITY

Dissections of the human stylohyoid chain were undertaken in order to correlate anatomic variations with clinical findings in reports concerning the etiology of the styloid syndrome, stylalgia, glossopharyngeal neuralgia, and other related conditions. Emphasis was placed upon the possible stressful relationships of neurovascular tissues in the space between the styloid process and the tip of the transverse process of the atlas. A narrowing of this gap, with pressure on intervening nerves and vessels, was seen as a possible cause of pain syndrome in the absence of an elongated styloid process or ossified stylohyoid ligament.

Variations in the configuration of the stylohyoid chain, which were at first thought to be merely interesting anatomic anomalies, were later recognized as possible causes of clinical symptoms. As early as 1907, Dwight[1] combined anatomic

A portion of this paper was presented at the fiftieth general session of the International Association for Dental Research, Las Vegas, Nev., March, 1972.

*Associate Professor, Department of Anatomy.

observations with findings reported in earlier clinical cases. He reviewed the embryology of the stylohyoid chain, noted some common variations in the resultant adult structures, and then made clinical deductions from a study of the cases.

The earliest significance attached to an unusual configuration of the stylohyoid chain was a surgical one, related to tonsillectomies, and involved the distal tips of elongated styloid processes. Later, other clinical symptoms and diagnostic factors were recognized as possibly being related to this anatomic entity. Eagle[2, 3] described two syndromes associated with an elongated styloid process. One was more common and occurred after tonsillectomy. Patients complained of several symptoms, including painful and difficult swallowing, pain referred to the ear, and sensation of a foreign body in the pharynx. The pain was thought to be due to stimulation of sensory nerve endings by scar tissue during healing in the tonsillar fossa. Diagnosis was by digital palpation of the elongated process in the fossa and by roentgenographic examination. Treatment consisted of an intraoral surgical technique that shortened the styloid process. Eagle's second syndrome[3, 4] was the carotid artery syndrome, which is found when the external or internal carotid artery is impinged upon by a curvature at the tip or in the shaft of an elongated styloid process. The resulting carotidynia was also alleviated by surgical shortening of the styloid process.

Graf[5] thought that complete or partial ossification of the stylohyoid ligament was one of the possible causes of glossopharyngeal neuralgia. He believed that, during the act of swallowing, the glossopharyngeal nerve could be pulled against the fixed bony strut and thus stimulated mechanically to produce the painful paroxysm.

Clinical symptoms related to the distal end of the stylohyoid chain have been described by Shenoi,[6] who applied the term *stylohyoid syndrome* when a persistent acute tenderness existed over the lesser cornu of the hyoid, where the stylohyoid ligament is attached. The cause was thought to be degenerative changes in the attached fibers of the ligament, since relief was obtained from local infiltration of corticosteroids.

Ossification of the stylohyoid ligament and fracture of the styloid process have been proposed by Freese and Scheman[7] as possible sources of referred pain in the region of the temporomandibular articulation.

The study presented here was conducted in an attempt to reveal by dissection the adult parts of the stylohyoid chain in their natural positions and relationships, without loss of parts resulting from osteologic preparation, or obscurity of structures due to angles or superimposition in radiologic techniques.[8, 9]

MATERIALS AND METHODS

Two hundred forty-one dissections of the stylohyoid elements were performed on adult human cadavers of both sexes. Lengths, deviations, joints, and relationships were examined. For measurements of the length of the styloid process, a common reference point at the posterior base, anterior to the stylomastoid foramen, was used. Measurements from this point included the root or proximal part of the styloid process, which is usually partially obscured anteriorly and

laterally by the bony sheath (vaginal process) of the tympanic portion of the temporal bone.

For observations of relationships between elements of the stylohyoid chain and the surrounding soft tissues, particular attention was given to facial, glossopharyngeal, vagus, cranial accessory, and hypoglossal nerves and to the carotid arteries and internal jugular vein.

Eleven specimens, selected because of the variation in their gross presentations, were removed for radiographic and histologic examination. After additional (postembalming) fixation for 1 week in 10 per cent neutral buffered formalin, the tissues were x-rayed and then decalcified in 5 per cent trichloroacetic acid. Paraffin sections were cut longitudinally at 6 to 10 microns and stained with either hematoxylin and eosin, Mallory's trichrome, or phloxine methylene blue.

Additional stylohyoid elements were removed and x-rayed for comparison with the specimens used for histologic studies. In some dissections, elongated styloid processes were fractured digitally through the floor of the tonsillar fossa, in order to determine the radiographic appearance of fractured styloids.

RESULTS

Extreme variations in the stylohyoid chain were observed. These included length of styloid processes, thickness of bony segments, angle and direction of deviation or bending, degree of ossification in different segments of the chain, and relationships of bone to soft tissues from the base of the skull to the hyoid bone.

The average length of 241 single, solid bars of styloid processes, measured from the posterior base, was 3.17 cm., with a range of 1.4 to 5.8 cm. (Fig. 1). The average length of sixty-eight of those from women was 2.97 cm., with a range of 1.4 to 5.5 cm. The average length of 173 of those from men was 3.26 cm., with a range of 1.6 to 5.8 cm. The height of the variably shaped bony sheath (vaginal process) which partially encloses the root or proximal part of the styloid process was included in measurements from the posterior base, thereby adding approximately 1 cm. to the length of the exposed (distal) part.

The thickness or diameter of bony segments, measured only on specimens of unusual appearance, varied from tapered sharp points at the tips of some styloids to about 1 cm. in other areas (Fig. 1), particularly in the basal region associated with the bony sheath. As verified on prepared skulls, the so-called sheath was hardly sheathlike. It consisted mostly of an anterolateral tympanic plate of the temporal bone and showed extreme variability in size, configuration, and relationship to the root of the styloid process.

In no case was the styloid process completely absent, although in several dissections it was obscured laterally by the bony sheath at the base. In these instances, stylohyoid and stylopharyngeal muscle fibers appeared to arise, in some measure, from the bony sheath. Occasionally, a normal styloid process, in linear combination with contiguous ossified or cartilaginous segments of the stylohyoid ligament, gave the apperance of greater length (Fig. 2).

Many apparently long styloid processes were segmented, showing a fibrous

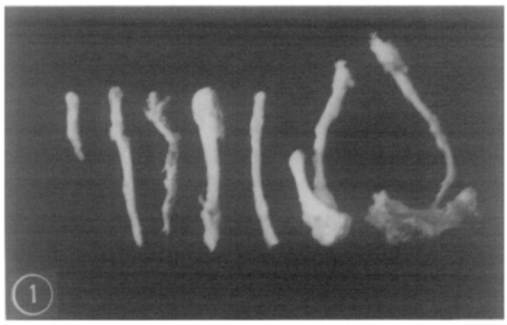

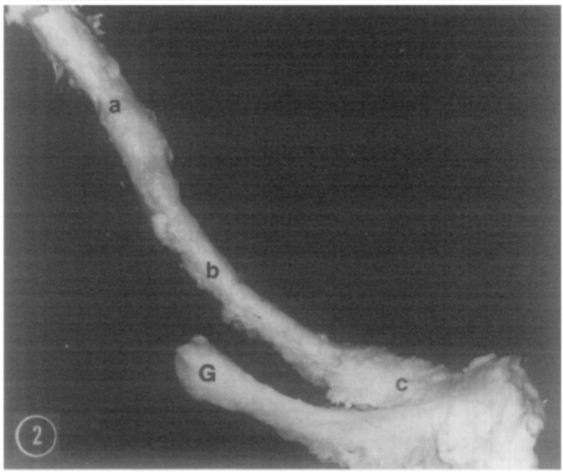

Fig. 1. A variety of dissected styloid processes and ossified stylohyoid ligaments. The one at the left is normal. The two at the right show portions of the attached hyoid bone at the distal end of the stylohyoid chain. (One third actual size.)

Fig. 2. A dissected stylohyoid chain in which the styloid process (*a*), stylohyoid ligament (*b*), and lesser cornu of the hyoid (*c*) appear grossly as a solid bar of bone. *G*, Greater cornu of hyoid bone.

union (syndesmosis) or a cartilaginous union (synchondrosis) between osseous segments. This was verified by radiographs (Fig. 3) and by histologic preparations. These joints provided various degrees of flexibility to what appeared grossly as elongated, solid bars of bone (Fig. 2). There were no instances of a solid bar of bone anchoring the hyoid bone to the base of the skull. On radiographs, fractures which occurred at the time of dissection were easily distinguished from short fibrous or cartilaginous unions between bony segments (Figs. 3 and 4).

Stylohyoid ligaments which lacked osseous, cartilaginous, or thickened fibrous segments were frequently difficult to identify. Stylomandibular ligaments, supposedly extending to the angle of the mandible, were rarely seen as typical ligamentous structures but, rather, as various modifications of deep cervical fascia. In contrast to the condition of many stylohyoid ligaments, no instances of ossification or calcification of the stylomandibular "ligament" were observed.

Styloid processes frequently showed a lateral or medial deviation. The tip of elongated processes occasionally appeared in, or against, the floor of the

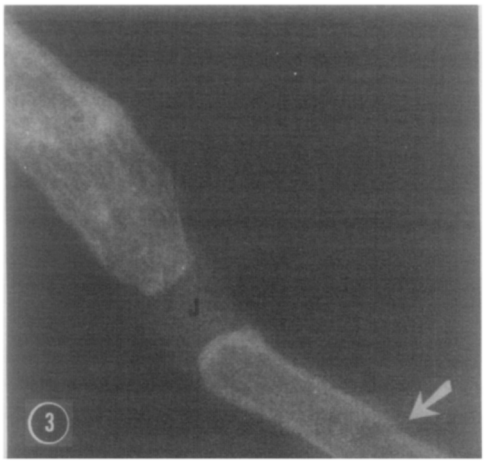

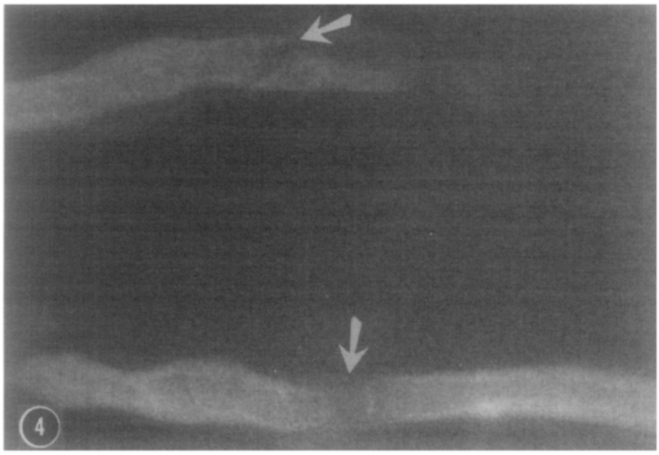

Fig. 3. Radiograph of part of the specimen in Fig. 2, showing a joint (*j*) between the styloid process and the ossified stylohyoid ligament. Note the fracture (*arrow*) which occurred at the time of dissection.

Fig. 4. Radiograph showing fracture (*top*) and joint (*bottom*) in two separate samples of elongated styloid processes.

tonsillar fossa when they curved or bent medially. Elongated processes, as well as some of normal length, sometimes displayed unusual intimate relationships with blood vessels, especially the external carotid artery below its final bifurcation into maxillary and superficial temporal branches. This was most evident when the process deviated laterally or exhibited a curve or bend along its course. The absolute degree of compression and constriction of vessels could not be determined, but in a few instances it appeared to be considerable.

An interesting relationship was seen between the styloid process (not necessarily elongated) and the tip of the transverse process of the atlas, the first cervical vertebra, shown on skeletal preparations in Figs. 5 and 6. Although the distance separating them was usually about 1 cm. or more, they were frequently much closer, especially when the styloid process was directed more vertically

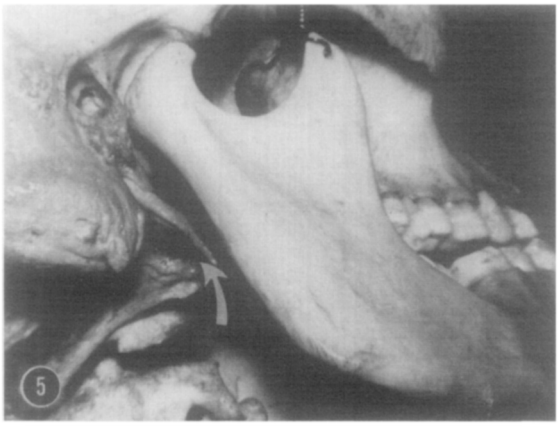

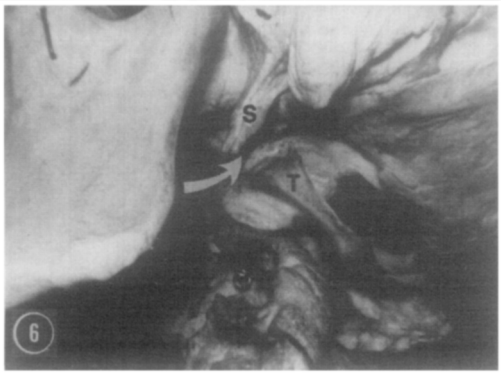

Fig. 5. Lateral view of a skull shows the close relationship that results in a narrow space between the styloid process and the tip of the transverse process of the atlas (*arrow*).

Fig. 6. An oblique, inferior angle of the narrow atlanto-styloid space (*arrow*) on another skeleton. *S,* Styloid process. *T,* Transverse process of the atlas.

and in the plane of the cervical vertebral column. In several of the dissections these bones were separated by a few millimeters or less. In one instance the space between the bony processes could scarcely accommodate the thickness of a scalpel blade, and in this space the internal carotid artery was compressed. Other major soft-tissue structures found in possible stressful relationships within this bony interspace were the ninth, tenth, eleventh, and twelfth cranial nerves and the internal jugular vein. It was interesting to notice that two out of seven whole-body skeletons in the dissection laboratories demonstrated this close atlantostyloid relationship (Figs. 5 and 6).

DISCUSSION

In this study, most of the 241 stylohyoid chains would have to be considered as being normal and without variations or stressful relationships which would have caused symptoms. Certain of the observations, however, would lead one to believe that many complaints could have existed, including various types of headache as well as other oral, facial, otic, pharyngeal, laryngeal, and cervical forms of pain and discomfort. Although some of these complaints could have

been caused by direct mechanical stress or stimulation of sensory nerve endings in healing tissues, others could have been cases of referred pain, particularly in areas of distribution of the glossopharyngeal nerve. The lack of medical histories precludes attempts to correlate anomalous structure with symptoms. But it is possible, after comparison with clinical findings in related research reports in the literature, to identify some anatomic variations of the stylohyoid chain which could be significant in the etiology of patients' complaints.

The most common and most easily observed variation is the elongated styloid process, usually found clinically without too much difficulty by radiography and by palpation. Dissections indicate, however, that a mere elongation of bone would not necesarily show a symptomatic relationship. The troublesome styloid process whose tip can be palpated at the floor of the tonsillar fossa not only must be elongated but must also show a medial deviation from the usual course. Also apparent was the fact that the mere presence of the tip of the styloid process in close apposition to the tonsillar fossa does not indicate that symptoms need necessarily follow.

The dissections reported here, as well as in other studies,[3-6, 10] indicate that important areas of potential clinical significance are those which lie in the course of the glossopharyngeal nerve, especially where the nerve is in intimate relationship with the styloid process and its attached structures. An elongated styloid process or ossified stylohyoid ligament could be instrumental in producing the symptoms associated with glossopharyngeal involvement, either by direct stress or by the mechanism of referred pain.[5, 10, 11] In consideration of the main course of the ninth cranial nerve and the distribution of its peripheral branches, the symptoms could be localized in such widely removed areas as the ear, base of the tongue, oropharynx, laryngopharynx, and the hyoid region of the neck.

The findings of this study would not support the practice of digitally fracturing an elongated styloid process as a treatment for reducing clinical symptoms.[2, 12] The effects of intentionally fracturing an elongated styloid process to relieve pain and discomfort could not be predicted, because of the extreme degree of variability of the process and its relationships. In addition to the possible damage which might result to a carotid artery or to the facial nerve if the fracture occurs too close to the base,[2, 3] there are many other closely related nerves, muscles, and blood vessels which might suffer damage, and thus the existing symptoms would be aggravated rather than alleviated. Eagle[3] recommended surgical shortening of the process exclusively, by means of the intraoral approach to the tonsillar fossa. He observed that "simple digital fracture of the process does not alleviate the symptoms," whereas "uniformly good results have been obtained by the surgical shortening of the process in all our patients."

The present study reveals that many additional soft structures, principally neurovascular, can be involved in possible stressful relationships within the atlantostyloid bony interspace. In addition to the glossopharyngeal nerve, these include the vagus, cranial accessory, and hypoglossal nerves, as well as the carotid arteries and the internal jugular vein.

In the correlation of an extensive dissection study with a thorough review of the clinical literature, it is obvious that the etiology of the styloid syndrome

has not yet been fully explained. While not attempting to describe in detail all the observations in this area, I think that it is important to record that the stressful relationships described near the base of the skull do not require the presence of an elongated styloid process. It is the direction of projection of the process rather than excessive length which could lead to symptomatic conditions in these cases. Thus, it is possible for patients with this anatomic anomaly to show signs of styloid syndrome without radiographic or palpable evidence of an elongated styloid process or ossified stylohyoid ligament, which would relate the pain syndrome to a "malpositioned" rather than "elongated" styloid process.[13] Radiographic interpretation is especially difficult in this area. Differential diagnosis awaits the further refinement of radiographic techniques, such as those used with the Panorex x-ray machine and its positioning apparatus.[14-16]

SUMMARY

Observations from 241 dissections of the human stylohyoid chain have been presented in which variations and relationships to surrounding tissues were noted. These findings were related to etiology and symptoms as reported by clinical investigators. Although most dissections revealed essentially normal conditions, there were many variations which could have caused complaints by the patients. These causes for complaint could have been due to direct mechanical pressure, stimulation of sensory nerve endings in healing tissues, or referred pain along areas of nerve distribution, especially the glossopharyngeal. In addition to the frequently reported involvement of an elongated styloid process, attention has been directed to possible stressful involvement of neurovascular elements in the more proximal atlantostyloid region, lateral to the transverse process of the first cervical vertebra (atlas). An unusual direction or curvature of the styloid process, rather than its elongation, was presented as a possible explanation for complaints by patients of "styloid syndrome" without radiographic or palpable evidence of an elongated process or ossified stylohyoid ligament.

I wish to express my appreciation to Dr. Milton Dines and Dr. Nicholas Darzenta for assistance with the photography and the radiography, respectively.

REFERENCES

1. Dwight, T.: Stylohyoid Ossification, Ann. Surg. **46**: 721-735, 1907.
2. Eagle, W. W.: Elongated Styloid Processes. Report of Two Cases, Arch. Otolaryngol. **25**: 584-587, 1937.
3. Eagle, W. W.: Elongated Styloid Process. Further Observations and a New Syndrome, Arch. Otolaryngol. **47**: 630-640, 1948.
4. Eagle, W. W.: Elongated Styloid Process. Symptoms and Treatment, Arch. Otolaryngol. **67**: 172-176, 1958.
5. Graf, C. J.: Glossopharyngeal Neuralgia and Ossification of the Stylohyoid Ligament, J. Neurosurg. **16**: 448-453, 1959.
6. Shenoi, P. M.: Stylohyoid Syndrome, J. Laryngol. Otol. **86**: 1203-1211, 1972.
7. Freese, A. S., and Scheman, P.: Management of Temporomandibular Joint Problems, St. Louis, 1962, The C. V. Mosby Company, pp. 106-110.
8. Stafne, E. C., and Hollinshead, W. H.: Roentgenographic Observations on the Stylohyoid Chain, ORAL SURG. **15**: 1195-1200, 1962.
9. Stafne, E. C.: Oral Roentgenographic Diagnosis, ed. 3, Philadelphia, 1969, W. B. Saunders Company, pp. 11-15.
10. Loeser, L. H., and Cardwell, E. P.: Elongated Styloid Process. A Cause of Glossopharyngeal Neuralgia, Arch. Otolaryngol. **36**: 198-202, 1942.

11. Asherson, N.: Glosso-Pharyngeal Neuralgia (Otalgia) and the Elongated Styloid Process: A Record of Five Cases, J. Laryngol. Otol. **71**: 453-470, 1957.
12. Lipshutz, B.: The Clinical Importance of Ossification of the Stylohyoid Ligament, J. A. M. A. **79**: 1982-1984, 1922.
13. Harma, R.: Stylalgia. Clinical Experiences of 52 Cases, Acta Otolaryngol. (Stockh.) [Suppl.] **224**: 149-155, 1967.
14. Smith, C. J., and Fleming, R. D.: A Comprehensive Review of Normal Anatomic Landmarks and Artifacts as Visualized on Panorex Radiographs, ORAL SURG. **37**: 291-304, 1974.
15. Manson-Hing, L. R.: The Stylohyoid Chain, ORAL SURG. **27**: 338-343, 1969.
16. Kaufman, S. M., Elzay, R. P., and Irish, E. F.: Styloid Process Variation. Radiologic and Clinical Study, Arch. Otolaryngol. **91**: 460-463, 1970.

Reprint requests to:
Dr. Jack Frommer
Department of Anatomy
Tufts University Schools of Medicine and Dental Medicine
136 Harrison Ave.
Boston, Mass. 02111