Fracture of the styloid process associated with mandibular fracture

A case report

U. Raman, T. Samraj
Department of Dental & Oral Surgery Christian Medical College and Hospital Vellore, India

Abstract. A case of styloid process fracture associated with bilateral mandibular fracture is reported. The possible fracture mechanism, clinical features, radiographic diagnosis and treatment are discussed.

Key words: styloid process; mandibular fracture

Accepted for publication 1 August 1990

Fracture of the styloid process of the temporal bone has been infrequently reported[1–5,7–11]. It can occur spontaneously without obvious relation to trauma[1,3,5,10,11], in association with mandibular fractures[4,8], as a result of blunt trauma[7,8,10], or during a surgical procedure, such as tonsillectomy[2]. The symptoms associated with a fractured styloid process are severe pharyngeal pain, diffuse facial pain, dysphagia, otalgia and limitation of mandibular movement[3,5,10,11]. Other findings include preauricular and/or peritonsillar swelling, trismus, and tenderness in the retromandibular fossa[11]. Fracture of the styloid process may be visualized by lateral oblique projection of the mandible, orthopantomograms, transpharyngeal radiography or tomographic techniques[8,11]. Therapy may be either conservative or surgical. Rest, soft diet, as well as intermaxillary fixation, and the application of a cervical collar have been recommended[8]. The elongated, fractured or dislocated styloid process may be removed surgically by a transpharyngeal approach through the tonsillar fossa[2,3].

Case report

An 18-year-old man was hit on the lower jaw by a cricket ball. He presented to the Oral Maxillofacial Surgery Department with pain and swelling of the face and with difficulties in opening his mouth and with swallowing.

Examination revealed a febrile young man with a diffuse, firm, tender swelling of the right retromandibular, submandibular and sublingual region. Opening of the mouth was limited to 20 mm interincisally. There was swelling in the right tonsillar region.

A lateral oblique view of the mandible and an orthopantomogram showed undisplaced fractures of the right mandibular angle, right styloid process (Fig. 1) and left mandibular body at the canine region. The patient was admitted and observed for 48 h until the swelling resolved. The mandible was immobilized by intermaxillary fixation. No active treatment was required for the styloid process fracture. Four weeks later, he was symptom free.

Discussion

Fracture of the styloid process is common. REICHART[11] suggests that extreme posterior displacement of the mandible that follows bilateral fracture dislocation, could result in direct contact between the cranial part of the fractured ramus and the styloid process. This impact could fracture the styloid process. Other predisposing factors have been attributed to such muscle uncoordinated supra and infra hyoid action as strained swallowing and severe coughing[11], elongation or imperfect ossification of the styloid process itself and unrecognised extrinsic or intrinsic trauma[3].

FROMMER[6] dissected 241 specimens of the stylohyoid chain in adult human

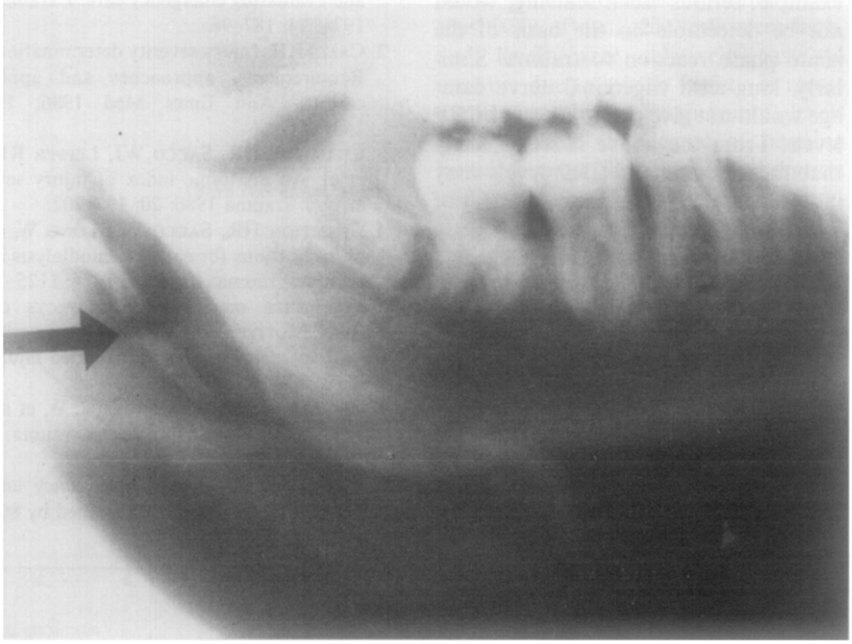

Fig. 1. Lateral oblique radiograph showing fractured styloid process.

cadavers to correlate anatomical variations with clinical findings. He observed that the styloid process frequently showed a medial or lateral deviation. Only a laterally deviated styloid process could conceivably come into direct contact with a posteriorly displaced fractured mandibular ramus.

Traction on the styloid process could be exerted through the stylomandibular ligament which attaches to the mandibular angle region. However, this ligament is a thickening of the cervical fascia and does not contain ligamentous structures[6]. This explains the rarity of a styloid process fracture in association with a mandibular fracture.

The 9th, 10th, 11th and 12th cranial nerves pass through a 1 cm gap between the styloid process and the tip of the transverse process of the first cervical vertebra[6]. These nerves are potentially vulnerable to trauma affecting the styloid process. Glossopharyngeal neuralgia and an atypical facial neuralgia have been reported in association with styloid process fracture[2,5].

The symptoms compatible with a styloid process fracture in the case presented were extreme dysphagia and swelling of the retromandibular region and tonsillar fossa. These fractures should alert the clinician to look for associated styloid process fracture.

The styloid process can be visualized by antero-posterior, lateral oblique radiographs, or panorex tomography[9,11]. The mandible, cervical spine and occipital bone, however, may obscure the styloid process.

Treatment is determined by the length of the styloid process, the degree of dislocation of the distal fragment and the presence of symptoms after the post immobilization phase[11]. In our case the styloid process was of normal length with no displacement of the distal fragment. Conservative treatment provided relief of symptoms after 4 weeks of immobilization.

References

1. Armao TA. Diagnosis and treatment of a styloid fracture. Oral Surg 1960: **13**: 1423–4.
2. Asherson N. Glossopharyngeal neuralgia (otalgia) and the elongated styloid process: A record of five cases. J Laryngol, Otol 1957: **71**: 453–47.
3. Babbit JA. Fracture of the styloid process and its tonsil fossa complications, with report of a case. Ann Otol Rhinol Laryngol 1933: **42**: 789–798.
4. Bird PD. Fracture of the styloid process secondary to fracture of the mandible. Br Dent J 1954: **5**: 67.
5. Douglas BL, Huebsch FC. Atypical facial neuralgia resulting from fractured styloid process of the temporal bone. Oral Surg 1953: **6**: 1199–201.
6. Frommer J. Anatomic variations in the stylohyoid chain and their possible clinical significance. Oral Surg 1974: **38**: 659–67.
7. Goodman TS. Fracture of an ossified stylohyoid ligament. Arch Otolaryngol 1981: **107**: 129–30.
8. Haidar Z, Kalamanchi S. Painful dysphagia due to fracture of the styloid process. Oral Surg 1980: **49**: 5–6.
9. McCorkell SJ. Fractures of the styloid process and stylohyoid ligament, an uncommon injury. J Trauma 1985: **25**: 1010–12.
10. McGinnis JM Jr. Fractures of an ossified stylohyoid bone. Arch Otolaryngol 1981: **107**: 460.
11. Reichart PA, Sooss W. Fracture of the styloid process of the temporal bone: An unusual complication of dental treatment. Oral Surg 1976: **42**: 150–4.

Address:
Dr. Uma Raman,
Department of Dental & Oral Surgery
Christian Medical College and Hospital
Vellore-632 004
India